
ORIGINAL ARTICLE**Relationship of Length of Clavicle and Crown-Rump Length***Anjali Gosavi¹*, P. R. Kulkarni²**¹Department of Anatomy, Ashwini Rural Medical College, Kumbhari, Dist. Solapur - 413237 (Maharashtra), India; ²Department of Anatomy, Government Medical College, Latur - 413512, (Maharashtra), India***Abstract:**

Background: When an incomplete fetal skeleton comes to the Anatomy department for its age estimation, it becomes difficult to arrive at the age due to lack of information in most of the standard textbooks of Anatomy and Forensic medicine. This study helps to arrive at the fetal age by certain formulae. *Aims of Study:* The estimate fetal age was determined by correlating the diaphyseal length of long bones with the Crown-Rump (CR) length of the fetus. *Material and Methods:* Thirty seven clavicles from fetuses ranging from 120mm to 310mm CR length were studied. Fetal bones were obtained by process of maceration of fetuses. Crown rump length was measured before the fetuses were subjected for maceration. Bones were dried at room temperature and length of clavicles of both sides was measured with caliper. *Results:* It was observed that clavicle grew at a rate of 0.13mm for every 1 mm increase in C.R. length. The regression coefficient and regression equations were worked out. *Conclusions:* It is possible to arrive at accurate fetal age by measuring the diaphyseal length of clavicle.

Key words: CR Length, Diaphyseal Length, Regression Equation, Regression Coefficient, Growth Rate of Clavicle.

Introduction:


Anatomists and skeletal biologists apply their knowledge of human variations to answer questions about skeletal age, sex, ancestry, stature, occupation, medical history, personal habits, health status and cause of death. A primary component of any skeletal analysis is to determine age and sex and anthropologist frequently must accomplish this task in face of incomplete or fragmentary skeletons. For this reason, developing, aging and sexing criteria from various skeletal elements have been a primary research focus in skeletal biology. Estimates of sub adult skeletal age are typically based on long bone length (diaphysis), epiphyseal fusion and dental development or eruption sequences and are more precise and accurate than adult age estimates based on degenerative changes at pubic symphysis, auricular surface, sternal rib ends, cranial sutures or dental attrition. However sex estimation is more accurate with adult skeletons than with sub adults. This work will explore age estimation of fetuses from clavicle in Maharashtra (India). Age estimation will focus on measurement of actual diaphysial length of fetal clavicles.

Material and Methods:

The present study was conducted on thirty seven apparently normal human fetuses of both sexes obtained from the Department of Obstetrics and Gynecology, Shri. Chatrapati Shivaji Maharaj General Hospital, Solapur.

All the specimens were fresh. Measurement of crown-rump length (CR length) was done immediately. The CR length was measured with the help of osteo metric board from vertex to tip of coccyx. The fetuses in the present study ranged from 120mm to 310mm CR length.

Each specimen was kept in a separately labeled container for maceration and removal of bones. After maceration the bones were collected and dried at room temperature. The bones collected for the present study were devoid of cartilaginous epiphysis ends and only the diaphysis was taken for measurement. The diaphyseal length of the long bones was measured with the help of venire caliper (Photograph -1). The bones of right and left sides were measured separately at least three times to avoid personal error. The mean of measurement of bones of two sides was obtained for finding the regression coefficient. Values of regression coefficient for each bone from thirty seven specimens were obtained separately so as to arrive at regres-



Photograph No. 1: Showing Measurement of Length of Fetal Clavicle

sion equation to find the CR length.

Results:

Clavicle:

Measurements of clavicle ranged from minimum 1.73cm to maximum 5.54cm with mean of 3.13cm for right clavicle and 3.04cm for left clavicle (Table 1). Correlation coefficient between C.R. length and clavicle was 0.938. Standard error (S.E) was calculated and was found to be negligible. Probable error (P.E) was also found to be negligible which is determined by the formula: $P.E=0.6745 \times S.E(r)$ where 0.6745 (r) is a constant. Significance level assessed was found to be highly significant (Graph No. 1 and 2). Regression equation derived is as follows

CR Length = 70.78 + 49.67 Clavicle. (Length in mm) Growth rate is 0.13mm per 1mm in-

Table 1: Measurements of CR Length and both the Clavicles

Sr. No.	Test	CRLength (cm)	Rt Clavicle (cm)	Left Clavicle (cm)
1.	Mean	22.65	3.13	3.04
2.	S.D.	44.02	0.85	0.95
3.	SEM	7.23	0.14	0.15

crease in C. R. length.

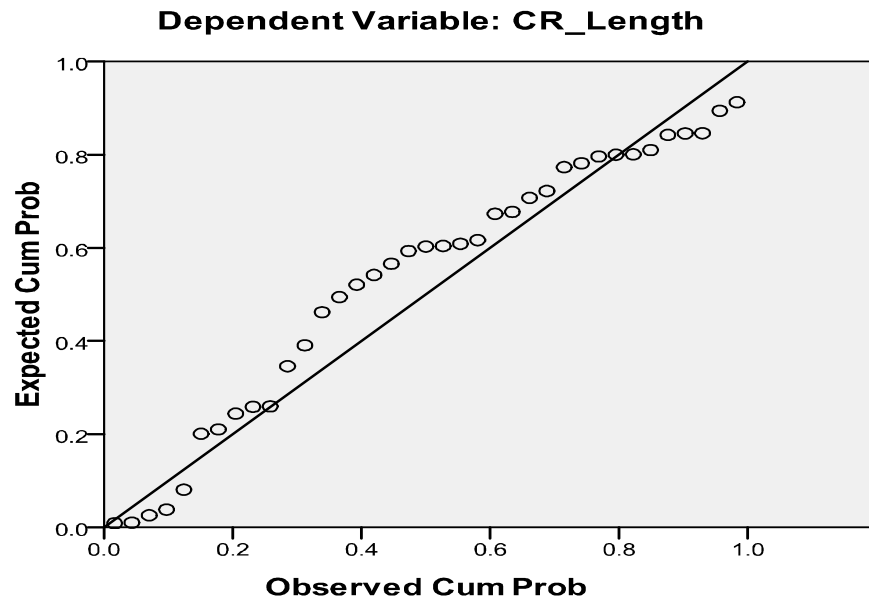
Discussion:

The diaphyseal length of long bones and its relation with crown-rump length helps to determine the age of the fetus.

The clavicle is considered as a long bone, as it has a shaft and an epiphysis at either end to permit the growth. The clavicle is the first fetal bone to undergo primary ossification, and its medial epiphysis is the last to fuse [1]. However, the clavicle ossifies via intramembranous

Graph1:

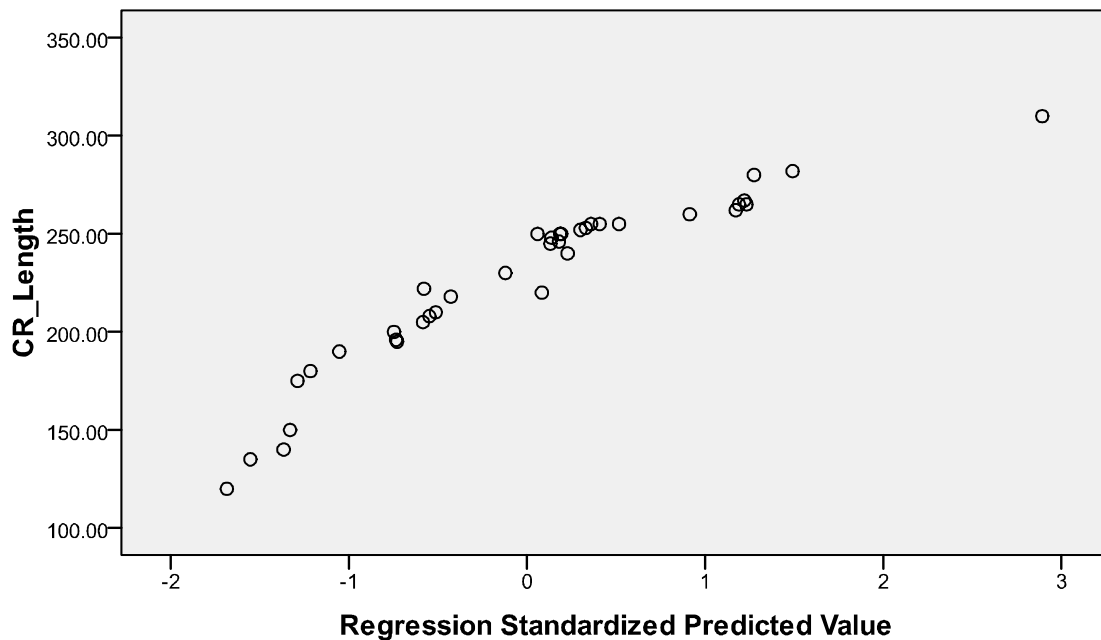
Normal P-P Plot of Regression Standardized Residual



Graph2:

Scatterplot

Dependent Variable: CR_Length



ossification with no prior endochondral ossification whereas other long bones undergo initial endochondral ossification [2]. The two primary ossification centers appear by the 6th intrauterine week and fuse together about one week later [3]. These two primary centers, medial and lateral which appear between 5th to 6th weeks of intrauterine life and fuse at about the 45th day [4]. After the osteoid matrix is laid down, cartilage appears at the acromial and sternal ends of the bone, at which point growth becomes a combination of endochondral and membranous ossification. The medial cartilaginous mass contributes more to clavicular growth in length than does the lateral mass, perhaps as much as 80% of the bone length [3]. The combination of the spatial location of the two ossification centers at either end of the bone and endochondral ossification at these sites gives the clavicle its unique s-shape by 8-9 prenatal weeks. The bone attains its adult form by 11 prenatal weeks [3]. Growth slows after birth until the growth spurt between 5 and 7 years, then slows again until the pubertal growth spurt [5]. Whenever a fetal bone is sent to an anatomist for opinion on the probable age of the fetus it becomes difficult to give an opinion on this aspect due to lack of information in most of the standard textbooks on embryology. Most of the studies on estimation of fetal age used radiological or ultrasonographic techniques [6-8] have studied the correlation of diaphyseal length of long bones and fetal age by ultrasonographic methods. These studies do not correlate the length of a dry long bone with the length obtained on radiography or ultrasonography. Therefore, present study was carried out on 37 dry fetal clavicles to find out correlation

between length of clavicle and C. R. length of fetuses to estimate fetal age for the Marathwada region [9] and observed a linear correlation between diaphyseal length of upper and lower limb bones and CR length. We could not compare the findings of present study because most of studies exclude clavicle.

Conclusion:

The regression equations worked out in the present study are as follows:

CR length = 70.78 + 49.67 clavicle.

Clavicle grows 0.13mm per one mm increase in CR length. It is observed in the present study that it is possible to calculate the fetal age from the diaphyseal length of clavicle.

References:

1. Humphrey L. Growth patterns in the modern human skeleton. *Am J Phys Anthropol* 1998; 105(1):57-72.
2. Kreitner K, Schweden F, Riepert T, Nafe B and Thelen M. Bone age determination based on the study of the medial extremity of the clavicle. *Eur Radiol* 1998; 8:1116-22.
3. Ogata S, Uhthoff H. The early development and ossification of the human clavicle-an embryologic study. *Acta Orthop Scand* 1990; 61(4):330-34.
4. David Johnson. Pectoral girdle, shoulder region and axilla: In Susan Standring (40th ed) Gray's Anatomy, Churchill Livingstone Elsevier. London UK, 2008: p 793.
5. Black S and Scheuer L. Age changes in the clavicle from the early neonatal period to skeletal maturity. *International Journal of*

Osteoarchaeology 1996; 6:425-434.

6. Russel J, Mattison A, Easso W *et al.* Skeletal dimensions as an indicator of foetal maturity. *Br Journal of Radio* 1972; 45:667-669.
7. Ming-Neng Yeh. Ultrasonic measurement of the femur length as an index of fetal gestational age. *Am J Obstret Gynaecol* 1982; 144(5):519-522.
8. Queenan JT, O'Brien GB. Ultrasound fetal femur length in relation with intrauterine growth retardation. *Am J Obstret Gynaecol* 1982; 144(1):35-39.
9. Vare AM, Bansal PC. Estimation of crown-rump length from diaphyseal length of fetal long bones. *J Anat Soc India* 1977; 26(2):91-93.

***Author for Correspondence:** Dr. Anjali Gosavi, Department of Anatomy, Ashwini Rural Medical College, Kumbhari. Dist. - Solapur. Cell: 09423593527
Email: dranjaligosavi@gmail.com